

## Aqueous Stem Bark Extract of *Spathodea campanulata* (P. Beauv) Modulates Carbon Tetrachloride Induced Hepatic Damage in Rats

<sup>1</sup>Charles Ansah, <sup>1</sup>Phyllis Elsie Dadzeasah and <sup>2</sup>Emmanuel Asiamah

<sup>1</sup>Department of Pharmacology, Faculty of Pharmacy and Pharmaceutical Sciences, College of Health Sciences, Kwame Nkrumah University of Science and Technology, Kumasi, Ghana

<sup>2</sup>Department of Histopathology, Komfo Anokye Teaching Hospital, Kumasi, Ghana

Received 2012-09-24, Revised 2013-05-22; Accepted 2013-05-27

### ABSTRACT

The objective of the present study was to evaluate the hepatoprotective and curative potential of the aqueous extract of the stem bark of *Spathodea Campanulata* (SCE) in a carbon tetrachloride-induced model of hepatotoxicity in rats. Rats pre-treated with 625 mg kg<sup>-1</sup>, 1250, 2500 mg kg<sup>-1</sup> or silymarin (50 mg kg<sup>-1</sup>) p.o for 3 days were intoxicated with CCl<sub>4</sub> (1 mL kg<sup>-1</sup>, 20% in liquid paraffin, p.o). In curative studies, rats received CCl<sub>4</sub> (1 mL kg<sup>-1</sup>, 20% in liquid paraffin, p.o daily) for 5 days before treatment with 100, 300 and 625 mg kg<sup>-1</sup> or silymarin 50 mg kg<sup>-1</sup> p.o daily for 3 days. In both the prophylactic and curative studies, significant hepatoprotective effects were obtained against liver damage induced by carbon tetrachloride as evident from decreased serum levels of Aspartate Aminotransaminase (AST), Alanine Aminotransferase (ALT), Gamma glutamyl transferase and bilirubin in the SCE treated groups (100, 300, 625 mg kg<sup>-1</sup>) and the silymarin group compared to the intoxicated controls. These results correlated well with the histopathology of liver for treated and control groups as well as the antioxidant protective capacity. The extent of lipid peroxidation assayed showed that TBA reactive substances increased significantly (six fold) in the carbon tetrachloride treated animals compared to the control. Treatment with the extract however restored TBA reactive substances to near normal at all three doses compared to the control. Additionally, the presence of phenols and the reducing power of the extract confirmed the antioxidant protective effect suggested by the reduction in lipid peroxidation. Administration of the extract (p.o) for seven consecutive days also significantly inhibited cytochrome P450 enzymes. The inhibitory effect on P450 enzymes possibly interfered with CCl<sub>4</sub> bioactivation and thus protected the hepatocytes. The present study thus suggests that aqueous stem bark extract of *Spathodea campanulata* significantly reverses CCl<sub>4</sub> hepatic damage in rats.

**Keywords:** *Spathodea Campanulata*, Carbon Tetrachloride (CCl<sub>4</sub>), Hepatoprotective Effect

### 1. INTRODUCTION

*Spathodea campanulata*, commonly referred to as African Tulip tree or Flame tree is located in the rainforest of equatorial Africa (Joly, 1985). The aqueous extract of *Spathodea campanulata* (P. Beauv) stem bark is reportedly used traditionally almost as a panacea. The bark infusion is used to treat dysentery and stomach ache; rubbings from the bark in treating oedemas, skin diseases

including herpes and for wound healing (Mensah *et al.*, 2006). It is also used to treat kidney disorders (Abbiw, 1990), as well as insulin and non-insulin dependent diabetes in Rwanda (Niyonzima *et al.*, 1999).

The widespread use of *Spathodea campanulata* in traditional medicine has prompted biological and pharmacological studies into the plant over recent years. *Spathodea campanulata* stem bark decoction has shown a hypoglycaemic activity in Streptozotocin (STZ)

**Corresponding Author:** Charles Ansah, Department of Pharmacology, Faculty of Pharmacy and Pharmaceutical Sciences, College of Health Sciences, Kwame Nkrumah University of Science and Technology, Kumasi, Ghana

induced diabetic mice (Niyonzima *et al.*, 1999) and also demonstrated activity on *Plasmodium berghei* in mice (Makinde *et al.*, 1988). It has also shown antibacterial activity against *B. subtilis*, *E. coli*, *P. aeruginosa* and *S. aureus* (Mensah *et al.*, 2006; Ofori-Kwakye *et al.*, 2009).

The use of *Spathodea campanulata* in traditional medicine has also been supported by the isolation and identification of some active chemical constituents including spathodol, (a new dihydroxylated sterol isolated from the leaves of *Spathodea campanulata*), oleanolic acid and pomolic acid (Mbosso *et al.*, 2008). Flavonoids, triterpenoids, diterpenoids and caffeic acid derivatives are also reported present in different parts of the plant (Houghton *et al.*, 2005).

While liver diseases continue to be a problem worldwide, conventional medications available for the management of liver diseases are limited. Among the drugs for liver injury, silymarin (a plant based preparation from *Silybum marianum*) is the most clinically popular in Europe (Kim *et al.*, 2007; Lieber *et al.*, 2003). Interestingly, orthodox medications for liver disorders are mainly from plant sources (Orhan *et al.*, 2007). Therefore the search for potent hepatoprotective agents from botanical sources is worthwhile.

We observed in a general toxicity assessment of *Spathodea campanulata* that treatment of rats with the aqueous stem bark extract of the plant profoundly reduced the ALT levels in rats (unpublished). We therefore reasoned that *Spathodea* could probably have a role in the management of liver diseases. The carbon tetrachloride-induced liver damage model, a model with extensive use and acceptability (Tsai *et al.*, 2008) was used in the study. Here we report on the prophylactic and curative effects of an aqueous extract of *Spathodea campanulata* on liver injury induced by carbon tetrachloride in rats.

## 2. MATERIALS AND METHODS

### 2.1. Chemicals/Reagents

Carbon tetrachloride, Sodium Dodecyl Sulphate, Acetic acid, Thiobarbituric Acid, Pyridine, n-butanol, 1,1,3,3-tetramethoxypropane, formalin and Sodium dihydrogen phosphate were purchased from Sigma (St. Louis, MO, U.S.A.), Silymarin, named Legalon 70 (from Bukwang Param, Seoul, Korea), was purchased from Bandy Chemist, a pharmaceutical company in Kumasi, Ghana.

### 2.2. Animals

The animals used in the study, Sprague-Dawley rats (150-220 g), were purchased from the Noguchi Memorial Institute for Medical Research, University of Ghana, Legon, Accra, Ghana and were maintained in the Animal house of the Department of Pharmacology, Kwame Nkrumah University of Science and Technology (KNUST), Kumasi. The animals were housed in groups of 6 in stainless steel cages (34×47×18 cm) and fed with normal commercial pellet diet (GAFCO, Tema), given water *ad libitum*. Approval for this study was obtained from the Ethical Review Committee, Department of Pharmacology, College of Health Sciences, Kwame Nkrumah University of Science and Technology, Kumasi, Ghana.

### 2.3. Preparation of Extract

*Spathodea campanulata* stem bark was collected at Kotei, a suburb of Kumasi near Kwame Nkrumah University of Science and Technology, Kumasi, Ghana in the month of October, 2008 and authenticated by Dr. Kofi Annan a Pharmacognosist at the Department of Pharmacognosy, Kwame Nkrumah University of Science and Technology, Kumasi, Ghana.

The stem bark was cut into smaller pieces and sun dried for nine days. The dried stem bark was milled in a hammer mill. The powdered stem bark (1000 g) was then extracted by decoction in water (3000 mL) for 30 min and the extract freeze-dried at the Centre for Scientific Research into Plant medicine, Mampong Akwapim, Ghana. The yield was 12.7% w/w. The freeze-dried extract, herein referred to as *Spathodea* or SCE, was then stored in a desiccator and was reconstituted in water immediately prior to use.

### 2.4. Effect of *Spathodea* on Carbon Tetrachloride Induced Hepatotoxicity

#### 2.4.1. Prophylactic Studies

This part of the study was conducted to assess the hepatoprotective action of SCE against CCl<sub>4</sub> induced liver damage. Thirty (30) rats were divided into six (6) groups (n = 5). SCE (625, 1250, 2500 mg kg<sup>-1</sup>) and silymarin (50 mg kg<sup>-1</sup>) were administered by oral gavage to the first four groups (A,B,C,D) at 48, 24 and 2 h before CCl<sub>4</sub> (20 % mixed with liquid paraffin, 1 mL kg<sup>-1</sup> p.o) administration. Group E was given only vehicle and group F received the same dose of CCl<sub>4</sub> to serve as the toxin control (Bremanti *et al.*, 1978; Chandan *et al.*, 2008). 24 h after CCl<sub>4</sub> administration, all animals were

ethanized and blood samples were collected from a common carotid into dry centrifuge tubes. Livers were then excised for tissue studies. The coagulated blood in the plain tubes were centrifuged and the serum was tested for liver markers including Total Protein (TP), Albumin (Alb), Globulin (Glob), bilirubin, Aspartate Aminotransferase (AST), Alanine Aminotransferase (ALT), Gamma Glutamyl Transferase (GGT) and Alkaline Phosphatase (ALP). Livers were preserved in 10% buffered (with  $\text{NaH}_2\text{PO}_4$ ) formalin for histopathology studies.

## 2.5. Curative Studies

Six groups of rats (A-F) ( $n = 5$ ) were used for the curative studies. Liver injury was induced by daily administration of  $\text{CCl}_4$  (20% in liquid paraffin;  $1 \text{ mL kg}^{-1}$  p.o) to groups (A-E) for five (5) consecutive days. Treatment was then initiated per gavage with *Spathodea* (100, 300, 625,  $\text{mg kg}^{-1}$ ), silymarin ( $50 \text{ mg kg}^{-1}$ ) and vehicle (liquid paraffin,  $1 \text{ mL kg}^{-1}$ ) to the same groups of animals at 2, 24 and 48h after the last  $\text{CCl}_4$  administration (Chandan *et al.*, 2008). Group F served as the normal control and so received only water throughout the experiment. Two (2) h after the last dose, all animals were euthanized and blood samples were collected from a common carotid into dry centrifuge tubes. Livers were then excised for tissue studies. The coagulated blood in the plain tubes were centrifuged and the serum was tested for liver markers including Total Protein (TP), Albumin (Alb), Globulin (Glob), bilirubin, Aspartate aminotransferase (AST), Alanine aminotransferase (ALT), Gamma Glutamyl Transferase (GGT) and Alkaline Phosphatase (ALP). Livers were preserved in 10% buffered (with  $\text{NaH}_2\text{PO}_4$ ) formalin for histopathology studies and TBARS assay.

## 2.6. Histopathology Studies

Liver samples from both prophylactic and curative treatments for control and treated groups of animals were washed separately with normal saline. They were fixed in 10% buffered (with  $\text{NaH}_2\text{PO}_4$ ) formalin for 24 h and used for the histology study. The method for processing was as reported by Galigher and Kozloff (1971). Briefly, livers were fixed for 12 h in Bouin's solution and processed for paraffin embedding using standard microtechniques. Sections of liver ( $5\mu\text{m}$ ) stained with haematoxylin and eosin (H and E) were observed under light microscope for histopathological changes.

## 2.7. Thiobarbituric Acid Reactive Substances (TBARS)

Portions of livers blotted of blood were homogenized in phosphate buffered saline (1/10 weight/volume) and centrifuged at 10000 g for 10 min at  $4^\circ\text{C}$ . Lipid peroxides (TBARS) in liver homogenate were estimated using thiobarbituric acid reactive substances (Ohkawa *et al.*, 1979). Sodium Dodecyl Sulphate (SDS) (0.2 mL of 8.1%), 1.5 mL of 20% Acetic acid and 1.5 mL of 0.8% TBA were added to 0.2 mL of tissue homogenate. The mixture was diluted to 4.0 mL with distilled water and heated in a water bath at  $95^\circ\text{C}$  for 60 min using a glass ball as a condenser. The mixture was left to cool after which 1.0 mL of water and 5.0 mL of n-butanol/pyridine mixture were added and shaken vigorously. The tube with its content was then centrifuged at 4000 rpm for 10 min. The organic layer was taken and its absorbance measured at 532 nm in a Shimadzu UV mini-1240, UV-VIS Spectrophotometer. The procedure was repeated using 1, 1, 3, 3-tetramethoxypropane as standard. The level of lipid peroxidation was expressed as moles of TBA reactants/100 g of wet tissue.

## 2.8. In Vitro Antioxidant Properties of *Spathodea*

### 2.8.1. Total Phenolic Content

The entire soluble phenols present in the total crude extract (0.1, 0.3, 1, 3  $\text{mg mL}^{-1}$  in distilled water) was measured by colorimetric assay using the Folin-Ciocalteu's phenol reagent as described by Benklebia (2005) with some modifications using tannic acid (0.01, 0.03, 0.1, 0.3  $\text{mg mL}^{-1}$  in distilled water) as standard. Four replicates each were used.

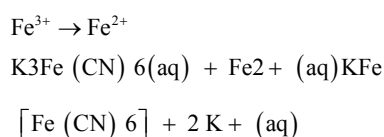
The test drug (1 mL) was added to 1 mL Folin-Ciocalteu's reagent (diluted tenfold in distilled water) in a test tube. The content of the test tube was mixed and allowed to stand for 5 min at  $25^\circ\text{C}$  in an incubator. 1.0 mL of 2% Sodium carbonate solution was added to the mixture. The reaction mixture was then allowed to stand for 2 h at  $25^\circ\text{C}$  in an incubator. It was then centrifuged at 3000 rpm for 10 min to obtain a clear solution. The absorbance of the supernatant was determined at 760 nm using a Shimadzu 1240 UV-VIS Spectrophotometer (Shimadzu Scientific Instruments).

Distilled water (1 mL) was added to 1 mL Folin-Ciocalteu's reagent (diluted ten-fold in distilled water) and processed in the same way as the test drugs and used as control. A sample of only distilled water served as the blank.

## 2.9. Reducing Power

The reducing power of the crude extract of *Spathodea* (0.1, 0.3, 1, 3 mg mL<sup>-1</sup>) was determined by its ability to reduce Fe<sup>3+</sup> to Fe<sup>2+</sup> (Oyaizu, 1986) according to the method described in literature by Amarowicz *et al.* (2005) with modifications using tannic acid (0.01, 0.03, 0.1, 0.3 mg mL<sup>-1</sup>) as standard.

The method determines the ability of a test compound to reduce Fe<sup>3+</sup> to Fe<sup>2+</sup>. The resultant Fe<sup>2+</sup> then reacts with ferricyanide ion to form a Prussian blue complex with maximum absorbance at 700 nm. The intensity of blue complex formed is directly proportional to the absorbance of the solution and reducing power of the test substance in solution:



The Tannic acid/extract solution (1 mL) was mixed with 2.5 mL of 0.2M sodium phosphate buffer (pH 6.6) and 2.5 mL of 1% potassium ferricyanide solution [K<sub>3</sub>Fe(CN)<sub>6</sub>(aq)] in a test tube. The mixture was incubated at 50°C for 20 min. Trichloroacetic Acid solution (TCA) (1.5 mL of 10 %) was added to the incubated mixture and centrifuged at 3000 rpm for 10 min.

The supernatant (2.5 mL) was mixed with 2.5 mL distilled water and 0.5 mL of 0.1% ferric chloride solution (FeCl<sub>3</sub> (aq)) in a test tube. The absorbance was then measured at 700 nm using Shimadzu 1240 UV-VIS spectrophotometer (Shimadzu Scientific Instruments).

Distilled water (1 mL) was added to 2.5 mL sodium phosphate buffer and 2.5 mL potassium ferricyanide [K<sub>3</sub>Fe(CN)<sub>6</sub>] in a test tube. This mixture was taken through the same procedure as were the test drugs and used as blank. Six replicates were used.

## 2.10. Effect of *Spathodea* on Total Cytochrome P450 Content

SD rats weighing 150-200 g were used for the experiment. Animals were divided and housed in groups of five for 5 days before treatment.

Group A received distilled water and served as control. Groups B, C and D received SCE (625 mg kg<sup>-1</sup>), ketoconazole (100 mg kg<sup>-1</sup>) and phenobarbital (100 mg kg<sup>-1</sup>) respectively daily p.o for seven consecutive days. On the eighth day, the animals were euthanized. Livers were removed, blotted of blood and homogenized in a 0.25M sucrose solution at a ratio of 5 mL g<sup>-1</sup> of tissue.

Phenyl Methane Sulphonyl Fluoride (PMSF) was added to inactivate serine proteases and the homogenate was centrifuged at 600 g for 5 min. Supernatant was further centrifuged at 12000 g for 10 min and the subsequent supernatant further centrifuged at 100,000 g for 1 h. The resultant pellets were suspended in 0.25 M sucrose. Protein concentration was adjusted to 20 mg mL<sup>-1</sup> using a modified Lowry method of protein assay. The cytochrome P450 level was then determined by forming the P450-carbon monoxide (CO) complex, CO, in a CO chamber leaving a non-CO complex control outside the chamber. The difference in absorbance at 450 and 490 was measured using a microplate reader. P450 levels were calculated as:

$$[\text{P450}] (\text{mM}) = (\Delta\text{Apc} - \Delta\text{Ap}) / 91$$

$\Delta\text{Apc}$  = The change in absorbance of the P450-CO complex

$\Delta\text{Ap}$  = The change in absorbance of the non-CO complex

## 2.11. Statistical Analysis

The results of hepatoprotective and antioxidant activities are expressed as mean  $\pm$  SEM. Results were statistically analysed using one-way ANOVA, followed by the Newman-Keuls Multiple Comparison Test.  $p < 0.05$  were considered significant

## 3. RESULTS

### 3.1. Effect of *Spathodea* on CCl<sub>4</sub> Induced Hepatotoxicity

#### 3.1.1. Prophylactic Studies

#### 3.1.2. Effect on Serum Enzymes

The effect of pre-treatment with *Spathodea campanulata* and silymarin on serum enzymes of CCl<sub>4</sub> intoxicated rats is shown in **Table 1**. The administration of a single dose of CCl<sub>4</sub> significantly increased the levels of AST ( $p < 0.01$ ) and ALT ( $p < 0.001$ ), compared to the untreated control. In the groups pre-treated with different doses of *Spathodea* or silymarin before CCl<sub>4</sub> intoxication, AST and ALT reduced significantly compared to the CCl<sub>4</sub>-only treated group. *Spathodea* at 625 mg kg<sup>-1</sup> also reversed the elevated GGT induced by CCl<sub>4</sub> treatment to normal levels (**Table 1**). Doses of *Spathodea* less than 625 mg kg<sup>-1</sup> did not have any significant effect in protecting the liver from the impending hepatotoxicity from CCl<sub>4</sub> (results not shown).



**Table 1.** Effect of *Spathodea campanulata* on some biochemical parameters of rats treated with extracts and silymarin before CCl<sub>4</sub> intoxication (prophylactic). Values are presented as the mean± SEM (n = 5).\*\*\*/+ indicates (p<0.001), \*\*/+ indicates (p<0.01). \*/+ indicates (p<0.05) compared to the control by Newman Keuls test. (+ significant compared to vehicle control; \* significant compared to toxin control)

Parameter	Vehicle control	CCl <sub>4</sub> control	SCE			Silymarin (50 mg kg <sup>-1</sup> )
			625 mg kg <sup>-1</sup>	1250 mg kg <sup>-1</sup>	2500 mg kg <sup>-1</sup>	
AST	163.2±12.58	452.3±29.85++	243.2±54.03	368.4±41.51	371.0±59.41	328.0±5.38
ALT	65.20±5.928	823.5±62.28+++	391.8±69.77*	551.8±139.1	578.4±131.3	378.8±107.2*
T. BIL	4.560±0.3982	4.80±0.5788	4.640±0.2619	5.00±0.1871	5.060±0.3108	4.640±0.4925
ALBUMIN	4.760±0.1166	4.673±0.0250	4.400±0.07071	4.440±0.1208	4.680±0.05831	4.480±0.0800
GGT	3.600±1.288	7.250±1.315	2.600±0.8124*	5.400±0.9274	3.400±0.6782	4.200±0.4899
ALP	278.4±9.244	463.5±12.69	403.0±22.03	470.8±125.0	389.8±29.35	454.0±83.77
PRO	8.300±0.7616	9.500±0.1683	9.280±0.08602	8.940±0.2379	9.620±0.1281	9.200±0.1761

AST = Aspartate Amino Transferase, ALT = Alanine Amino Transferase, T.BIL = Total biliRubin, GGT = Gamma Glutamyl Transpeptidase, ALP = Alkaline phoSphatase, PRO = Total Protein

### 3.2. Histopathological Examination of the livers of Rats Pre-Treated with *Spathodea* and Silymarin before CCl<sub>4</sub> Treatment

Liver sections taken from untreated CCl<sub>4</sub>-injured rats had profound inflammatory infiltration, hepatocyte coagulative necrosis and fibrous septa compared to that from the healthy control group (Fig. 1). Qualitative and quantitative histological analysis showed that silymarin and *Spathodea* (625 mg kg<sup>-1</sup>) markedly improved the degree of hepatic fibrosis in CCl<sub>4</sub>-injured rats. Treated groups displayed delicate fibrous septa and lower collagen levels than untreated CCl<sub>4</sub>-injured group. There was mild cellular degeneration, necrosis and inflammation in the group treated with 625 mg kg<sup>-1</sup> *Spathodea*. Animals treated with 1250 mg also showed mild cellular degeneration, necrosis and inflammation. The silymarin (50 mg kg<sup>-1</sup>) group suffered mild inflammation and cellular degeneration with very mild necrosis. In the CCl<sub>4</sub> control group, there was moderate cellular degeneration and necrosis, inflammation and fibrosis than in all the treatment groups.

### 3.3. Curative Studies

#### 3.3.1. Effect on Serum Markers

The effect of *Spathodea* in modulating CCl<sub>4</sub> induced hepatotoxicity is shown in Table 2. The administration of *Spathodea* and silymarin significantly reduced the AST, ALT and total bilirubin induced by CCl<sub>4</sub> compared to the normal control by Newman Keul's test. The decrease was profound at lower doses. The extract and silymarin however did not significantly decrease the elevated Blood Urea Nitrogen (BUN) (Table 2). GGT and total proteins were not significantly affected by the toxin.

### 3.4. Histopathology Studies

Liver sections from CCl<sub>4</sub>-injured rats had more inflammatory infiltration, steatosis and coagulative necrosis than healthy control group (Fig. 2). The extract at 100 and 300 mg kg<sup>-1</sup> respectively did not show significant improvement over the effect of CCl<sub>4</sub> on the liver. Though the extent of steatosis improved in the *Spathodea*-treated group especially at the 625 mg kg<sup>-1</sup> dose, liver architecture (coagulative necrosis) did not change. Similarly, cellular degeneration, necrosis and inflammation were mild in the 625 mg kg<sup>-1</sup> treated group. The standard drug (silymarin) treated group also showed considerable improvement in fatty infiltration.

### 3.5. Lipid Peroxidation

TBA reactive substance level (Fig. 3) increased significantly in the carbon tetrachloride treated animals relative to the control to nearly six fold (p<0.001). The increase was reversed to near normal with *Spathodea* at all doses compared to the control (p<0.001).

### 3.6. *In vitro* Antioxidant Properties of *Spathodea*

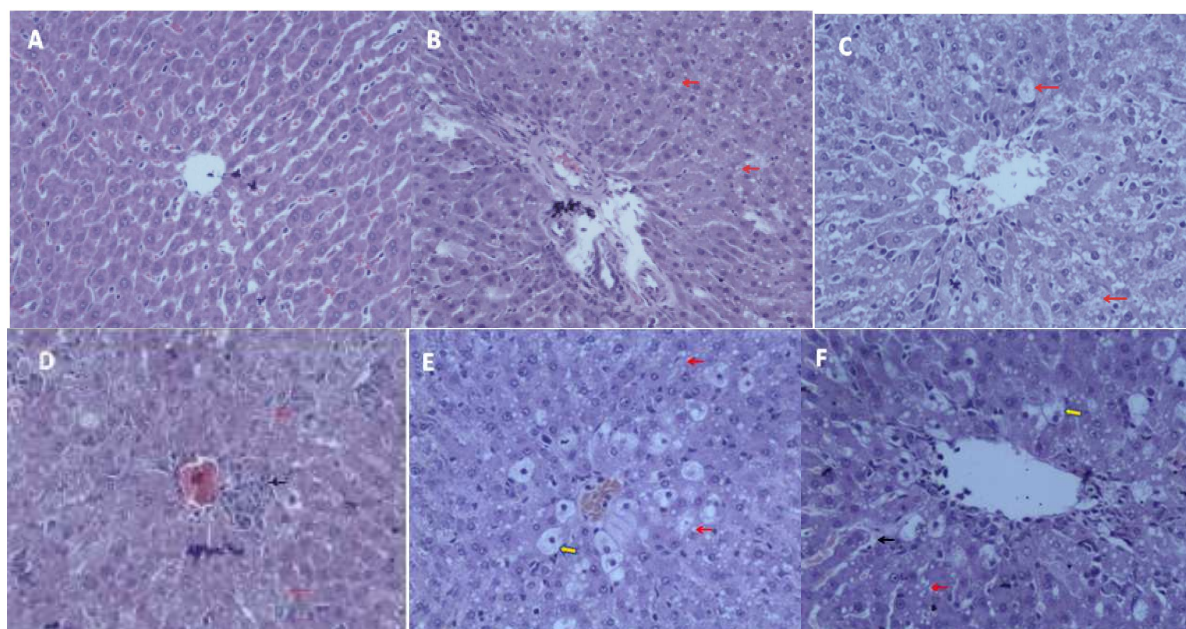
#### 3.6.1. Total Phenolic Content

The total phenol content of tannic acid (0.01- 0.3 mg mL<sup>-1</sup>) expressed as absorbance increased with increasing concentration ( $r^2 = 0.97$ ) (Fig. 4). *Spathodea* (0.1-3.0 mg mL<sup>-1</sup>) also showed a dose dependent increase in phenolic content (0.0009±0.00006 to 0.0856±0.0012) expressed as tannic acid equivalent. The content of total phenols in the extract was however found to be lower than that of the tannic acid.

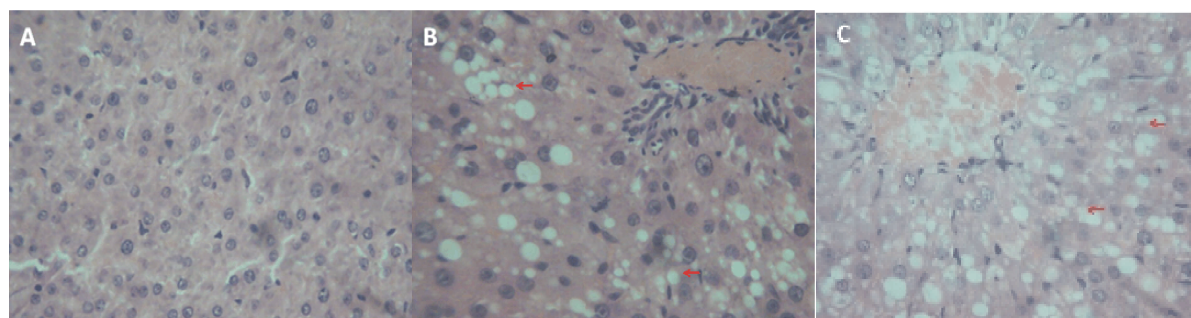
**Table 2.** Effect of *Spathodea campanulata* and Silymarin on biochemical parameters of rats treated with CCl<sub>4</sub> (curative). Values are expressed as means ± SEM (n = 5), \*\*\* indicates significance (p<0.001) and \*\* indicates (p<0.01). (+ Significant compared to normal control, \*Significant compared to toxin control)

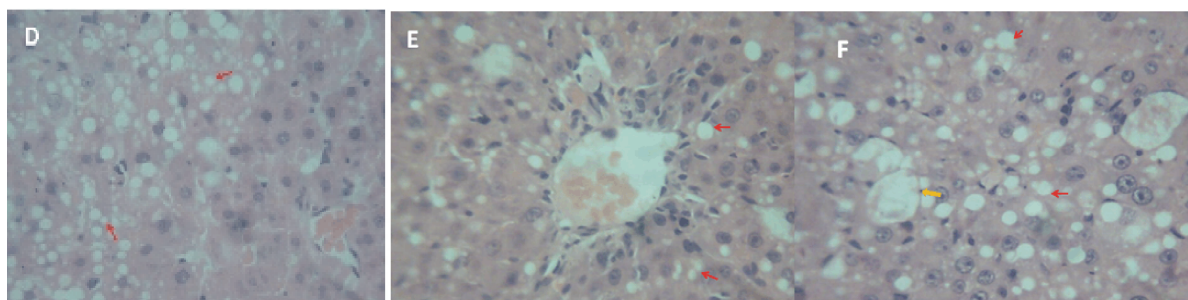
Parameter	Normal control	CCl <sub>4</sub> control	SCE			Silymarin (50 mg kg <sup>-1</sup> )
			100 mg kg <sup>-1</sup> SCE	300 mg kg <sup>-1</sup> SCE	625 mg kg <sup>-1</sup> SCE	
AST	214.5±17.27	592.5±120.0+++	235.3±19.03**	266.9±13.06**	437.9±20.94	382.8±17.24*
ALT	133.5±9.441	577.0±161.9++	190.5±15.25**	202.3±26.88**	295.7±22.51*	278.9±13.57*
Total Protein	61.80±.235	66.96±1.739	60.64±2.179	61.58±2.127	77.62±1.573	72.34±1.725
Total Bilirubin	1.50±0.100	3.740±0.419+++	1.660±0.093***	2.220±0.2518**	3.620±0.447	2.420±0.153**
BUN	5.222±0.2217	10.42±0.425+++	7.646±0.558	11.52±1.423	9.266±0.503	8.752±0.769
GGT	0.0±0.0	1.960±0.625	1.940±1.018	1.940±0.498	2.920±1.058	2.540±1.364

AST = Aspartate Amino Transferase, ALT = Alanine Amino Transferase, BUN = Blood Urea Nitrogen, GGT = Gamma Glutamyl Transpeptidase

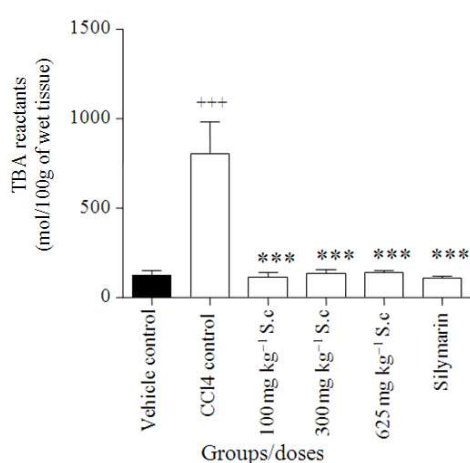


**Fig. 1.** Photomicrograph (×400) showing histopathological profile of the livers of rats in SCE prophylactic treatment. Sections of the liver after treatment with *Spathodea campanulata* stem bark extract/Silymarin before CCl<sub>4</sub> intoxication. (A) Normal Control, liver from rat treated with saline shows normal cellular architecture with distinct hepatic cells, (B) 625 mg kg<sup>-1</sup>, (C) 1250 mg kg<sup>-1</sup>, (D) 2500 mg kg<sup>-1</sup>, (E) Silymarin, (F) CCl<sub>4</sub> Control.(→) Indicates macrovesicular steatosis, (→) indicates steatosis (fatty liver), (→) indicates fibrous septa





**Fig. 2.** Photomicrograph (×400) showing histopathological profile of the livers of rats treated with CCl<sub>4</sub> followed by SCE treatment (curative treatment)



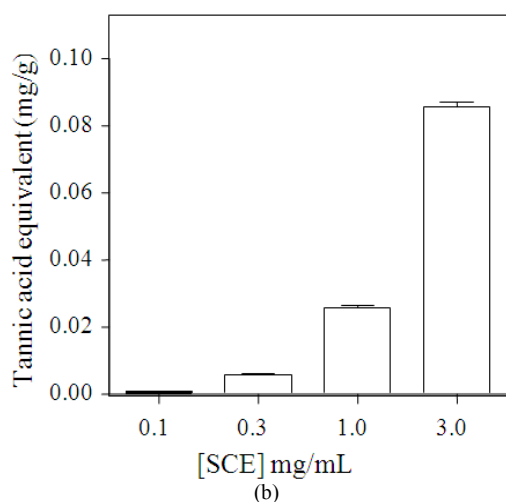
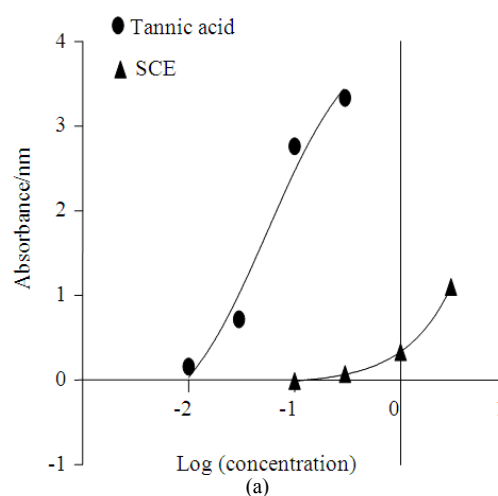
**Fig. 3.** Changes in TBARS level in normal and experimental rats. Values represent mean ± SEM for five animals in each group. Values are statistically significant at +++ p<0.001 when compared with the vehicle control and \*\*\* p<0.001 when compared with the toxin control

### 3.7. Reducing Power

The extract at 0.1- 3 mg mL<sup>-1</sup> and the standard antioxidant Tannic acid at 0.01 -0.3 mg mL<sup>-1</sup> dose dependently reduced Fe<sup>3+</sup> to Fe<sup>2+</sup> resulting in dose dependent increase in absorbance (Fig. 5). The EC<sub>50</sub> showed that the extract (with EC<sub>50</sub> of 1071 mg mL<sup>-1</sup>) is approximately 100 fold less potent than the standard drug Tannic acid (EC<sub>50</sub> of 10.87 mg mL<sup>-1</sup>).

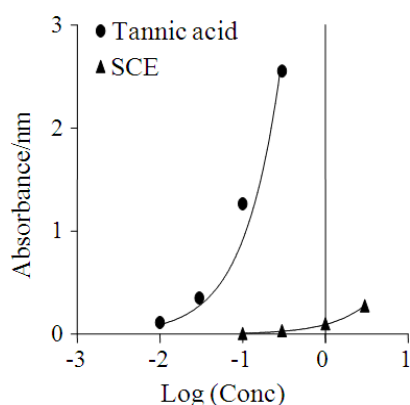
### 3.8. Effect on Total Cytochrome P450

Treatment of rats with Spathodea resulted in a profound decrease in the total cytochrome P450 enzyme content in the liver (Fig. 6). The decrease was comparable to ketoconazole a known inhibitor of cytochrome P450. Phenobarbital (an inducer) increased the total cytochrome P450 enzymes compared to the control.

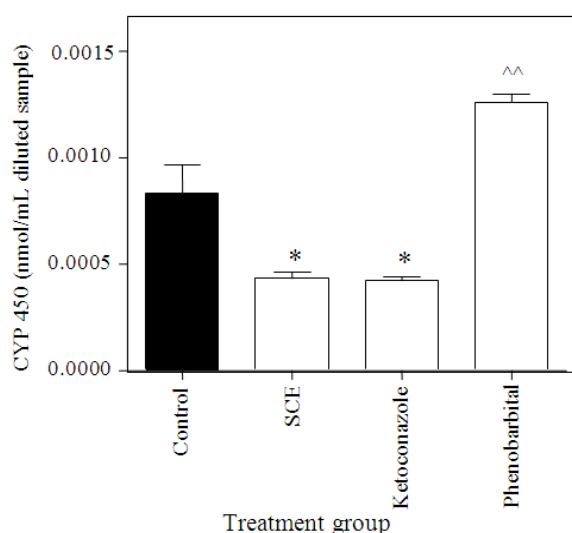


**Fig. 4.** (a) Log (concentration) against absorbance of tannic acid and SCE and (b) Total phenolic content of SCE (0.1-3.0 mg kg<sup>-1</sup>) expressed as tannic acid equivalent (mg/g extract). Each point represents the mean ± SEM (n = 4)





**Fig. 5.** Reducing power of SCE (0.1-3.0 mg kg<sup>-1</sup>) compared with tannic acid (0.01-0.3 mg kg<sup>-1</sup>). Each point represent the mean ± SEM (n = 3)



**Fig. 6.** Effect of SCE treatment on total liver cytochrome P450 content in rats. Values are presented as the mean ± SEM (n = 5). \* indicates significant decrease (p<0.05) compared to the control; and ^^ indicates significant increase (p<0.01) compared to the control

#### 4. DISCUSSION

The liver is a multipurpose organ in the body involved in the breakdown of toxins in the body. Damage to the liver inflicted by hepatotoxic agents is therefore of critical consequence. The changes associated with CCl<sub>4</sub>-induced liver damage are comparable to that of acute viral hepatitis (Rubinstein, 1962), consequently CCl<sub>4</sub>-mediated hepatotoxicity was employed as the

experimental model for liver injury. The CCl<sub>4</sub> model for hepatotoxicity has been extensively studied. It is now established that CCl<sub>4</sub> accumulates in hepatic parenchymal cells and is metabolically activated by cytochrome P-450 dependent monooxygenases to form a trichloromethyl free radical (CCl<sub>3</sub>·). This radical alkylates cellular proteins (including cytochrome P450) and other macromolecules (Bishayee *et al.*, 1995) with a concurrent attack on polyunsaturated fatty acids in the presence of oxygen to generate lipid peroxides (Bishayee *et al.*, 1995; Recknagel, 1983) leading to liver damage.

For many years now, hepatotoxic compounds such as CCl<sub>4</sub> have been known to cause marked elevation in serum transaminases.

In agreement with results obtained in similar investigations (Bishayee *et al.*, 1995), CCl<sub>4</sub> in the present study elicited a significant increase in the levels of serum transaminases (ALT, AST and GGT). This was evident in both prophylactic and curative studies.

Administration of the extract to rats before intoxication was to determine if the extract has the ability to condition the hepatocytes to promote accelerated regeneration of parenchymal cells, thus protecting against membrane fragility and decreasing the leakage of marker enzymes into the circulation in the event of CCl<sub>4</sub> intoxication.

The increase in ALT in the CCl<sub>4</sub> group (in the prophylactic studies) was about thirteen fold that of the control whereas AST increased about three fold in the CCl<sub>4</sub> group compared to the control. The two enzymes most often associated with hepatocellular damage are AST and ALT. ALT is specifically produced in the hepatocytes, making it relatively a better determinant of hepatic injury as opposed to the AST, which is observed in higher levels in a variety of tissues such as liver, muscle and red blood cells. Consequently, muscle injury/trauma (intra muscular injections, severe restraint during handling) and haemolysis can lead to significant AST elevations (Ramaiah, 2007). Again, AST has a shorter half-life of about 12 h while ALT has a half-life of about 60 h (Meyer and Harvey, 2004). The lowest dose (prophylactic studies), 625 mg kg<sup>-1</sup>, significantly decreased the elevated ALT, AST and GGT, but not higher doses. Lower doses than 625 mg kg<sup>-1</sup> (100 and 300) had no effect on the liver prophylactically. Silymarin in all cases decreased the degree of toxicity, which was comparable to the Spathodea extract.



The liver has the capacity to regenerate when left alone after intoxication especially in acute toxicity (Timbrel, 2009) consequently, the rats were given five doses to ensure that toxicity to the liver is sustained before treatment was commenced. There was considerable increase in the AST and ALT in the curative study by CCl<sub>4</sub>. The 625 mg kg<sup>-1</sup> of the extract and silymarin (50 mg kg<sup>-1</sup>) reduced AST and ALT levels significantly, confirming the efficacy of lower doses of the extract as in the prophylactic study. Although ALT is markedly more specific for liver function as stated earlier, nevertheless serum levels of AST and ALT rise and fall in parallel (Rose *et al.*, 2007).

Gamma Glutamyl Transferase (GGT) level was raised after the administration of CCl<sub>4</sub> in the prophylactic treatment but was unaffected in the curative study. GGT and ALP are employed to detect impaired bile flow (cholestasis). Impaired bile flow caused by drugs and other toxins evoke increased synthesis of these enzymes within hours, which are released into the circulation by unknown mechanisms (Ramaiah, 2007).

Total serum bilirubin can also be employed to detect cholestasis in addition to the GGT and ALP as well as in hepatocellular damage (Ramaiah, 2007). Unlike the prophylactic studies, total bilirubin levels in the serum of the rats increased significantly in the toxin control in the curative studies. This increase was reduced to normal levels by doses of 100 and 300 mg kg<sup>-1</sup> of extract as well as silymarin.

The administration of CCl<sub>4</sub> did not affect the serum total protein levels in both the prophylactic and curative studies. Between one and 3 h after dosing with carbon tetrachloride, triglycerides accumulate in hepatocytes, detectable as fat droplets and there is continued loss of enzyme activity in the endoplasmic reticulum (Timbrel, 2009). As expected, liver sections from untreated CCl<sub>4</sub> -injured rats had higher degree of inflammation and fibrous septa than the treated groups. Rats that received 625 and 1250 mg kg<sup>-1</sup>, in the prophylactic studies, showed mild cellular degeneration, necrosis and inflammation. In the highest dose however, cellular degeneration was more pronounced comparable to the untreated CCl<sub>4</sub> group with mild necrosis and fibrosis. It is possible that at high doses of the extract, the effect of some components of the extract with potential toxicity become more pronounced. The silymarin treated animals showed very mild inflammation and cellular degeneration and fibrosis. Extract treated groups showed delicate fibrous septa and lower collagen levels than untreated CCl<sub>4</sub>-injured rats.

Light microscopic studies confirmed the curative potential of *Spathodea* against CCl<sub>4</sub> induced liver damage as evident by the reversal of centrilobular necrosis, macrovesicular fatty changes (steatosis) and inflammation in hepatic parenchyma after CCl<sub>4</sub> administration.

CCl<sub>4</sub> intoxication in various studies has demonstrated that CCl<sub>4</sub> causes free radical generation in many tissues such as liver, kidney, brain, heart lung and blood (Ganie *et al.*, 2011). Carbon tetrachloride (CCl<sub>4</sub>) is biotransformed by the cytochrome P450 enzymes to the trichloromethyl (CCl<sub>3</sub>·) radical, a hepatotoxic metabolite. Covalent binding of this radical to proteins initiates a cascade of events leading to cell necrosis.

Antioxidants have been shown to protect cellular DNA against oxidative stress by reducing the level of free radicals in the cells and increasing the level of typical antioxidant enzymes (Awad *et al.*, 2008). Indeed the elevation in the levels of the end products of lipid peroxidation (MDA) in CCl<sub>4</sub>-treated rat livers was reversed by treatment with the extract. The increase in MDA levels in the liver implied enhanced peroxidation leading to tissue damage and malfunction of the antioxidant defence mechanisms (Naik and Panda, 2007).

Among the many drugs for liver injury, silymarin is the most clinically popular and is known to have hepatotherapeutic and anti-fibrotic properties (Kim *et al.*, 2007). Silymarin has also shown effectiveness in several studies, such as protection against genomic injury and increasing hepatocyte protein synthesis. It is also known to prevent lipid peroxidation in some experimental models (Soto *et al.*, 1998). Some authors are however of the view it has a low bioavailability (Comoglio *et al.*, 1995; Giacomelli *et al.*, 2002). The present results suggest that the mechanism of hepatoprotection of *Spathodea* may at least in part be due to its antioxidant properties evidenced by the ability to reduce lipid peroxidation in CCl<sub>4</sub> injured rats. The reducing power and total phenolic content which were tested in the *in vitro* antioxidant experimental models further supports this assertion. An examination of whether SCE can reduce Fe<sup>3+</sup> to Fe<sup>2+</sup> gave a positive result. The reduction of Fe<sup>3+</sup> to Fe<sup>2+</sup> is a property of antioxidants. They are able to donate electrons to reactive radicals converting them into more stable and unreactive species (Cetinkaya *et al.*, 2011). This is the reducing power of the antioxidant. The extract also has an appreciable level of phenolic compounds according to the total phenolic test. Phytochemicals such as flavonoids and other polyphenol constituents of plants have been

reported to be effective radical scavengers and inhibitors of lipid peroxidation (Dai and Mumper, 2010; Ebrahimzadeh *et al.*, 2010). Phenolic compounds are the most wide spread secondary metabolites in the plant kingdom. These diverse groups of compounds have received much attention as potential natural antioxidants in terms of their ability to act as both efficient radical scavengers and metal chelators. It is reported that the antioxidant activity of phenols is largely due to their redox properties, hydrogen donors and singlet oxygen quenchers (Rice-Evans *et al.*, 1995). The presence of phenols together with the reducing ability of the extract in addition to the DPPH scavenging activity (Houghton *et al.*, 2005) shows that SCE has antioxidant properties which may be responsible for its hepatoprotective activity.

In addition, the inhibition of cytochrome P450 by the extract could play an important role in prevention of hepatotoxicity. Since carbon tetrachloride has to be activated by CYP 450 to tri-chloro methyl radical before the hepatotoxic effect can be exerted, inhibition in the activity of CYP450, a property of SCE, can therefore decrease the susceptibility of the liver to hepatic injury from CCl<sub>4</sub>.

## 5. CONCLUSION

This study has demonstrated that the aqueous stem bark extract of *Spathodea campanulata* has the capacity to modulate carbon tetrachloride induced hepatic damage in rats. The study further suggests that the protective activity of the extract is linked to its antioxidant activity and inhibition of CYP450, the enzymes involved in the bioactivation of CCl<sub>4</sub>.

## 6. ACKNOWLEDGEMENT

The researchers are very grateful to Mr. Thomas Ansah of the Department of Pharmacology, KNUST for his technical support.

## 7. REFERENCES

- Abbiw, D.K., 1990. Useful plants of Ghana: West African Uses of Wild and Cultivated Plants. 1st Edn., Intermediate Technology Publications, Kew, ISBN-10: 1853390437, pp: 337.
- Amarowicz, R., A. Troszynska and F. Shahidi, 2005. Antioxidant activity of almond seed extract and its fractions. *J. Food Lipids*, 12: 344-358. DOI: 10.1111/j.1745-4522.2005.00029.x
- Awad, A.B., S.L. Barta, C.S. Fink and P.G. Bradford, 2008.  $\beta$ -Sitosterol enhances tamoxifen effectiveness on breast cancer cells by affecting ceramide metabolism. *Mol. Nut. Food Res.*, 52: 419-426. DOI: 10.1002/mnfr.200700222
- Benklebia, N., 2005. Free-radical scavenging capacity and antioxidant properties of some selected onions (*Allium cepa* L.) and Garlic (*Allium sativum* L.) extracts. *Brazilian Arch. Biol. Technol.*, 48: 753-759. DOI: 10.1590/S1516-89132005000600011
- Bishayee, A., A. Sarkar and M. Chatterjee, 1995. Hepatoprotective activity of carrot (*Daucus carota* L.) against carbon tetrachloride intoxication in mouse liver. *J. Ethnopharmacol.*, 47: 69-74. DOI: 10.1016/0378-8741(95)01254-B
- Bremanti, G., W. Murmann, P. Pierini and M. Comporti, 1978. Effect of cicloxicilic acid on CCl<sub>4</sub>-induced liver injury. *Arzneimittel Forschung*, 28: 1212-1217. DOI: 10.1016/0378-8741(95)01254-B
- Cetinkaya, Y., H. Gocer, A. Menzek and I. Gulcin, 2011. Synthesis and antioxidant properties of (3,4-Dihydroxyphenyl)(2,3,4-trihydroxyphenyl)methanone and its derivatives. *Archiv der Pharmazie (Weinheim)*, 345: 323-334. DOI: 10.1002/ardp.201100272
- Chandan, B.K., A.K. Saxena, S. Shukla, N. Sharma and D.K. Gupta *et al.*, 2008. Hepatoprotective activity of *Woodfordia fruticosa* Kurz flowers against carbon tetrachloride induced hepatotoxicity. *J. Ethnopharmacol.*, 119: 218-224. DOI: 10.1016/j.jep.2008.06.020
- Comoglio, A., A. Tomasi, S. Malandrino, G. Poli and E. Albano, 1995. Scavenging effect of silipide, a new silybin-phospholipid complex, on ethanol-derived free radicals. *Biochem. Pharmacol.*, 50: 1313-1316. DOI: 10.1016/0006-2952(95)02001-S
- Dai, J. and R.J. Mumper, 2010. Plant phenolics: Extraction, analysis and their antioxidant and anticancer properties. *Molecules*, 15: 7313-7352. DOI: 10.3390/molecules15107313
- Ebrahimzadeh, M.A., S.M. Nabavi, S.F. Nabavi, F. Bahramian and A.R. Bekhradnia, 2010. Antioxidant and free radical scavenging activity of *H. officinalis* L. var. *angustifolius*, *V. odorata*, *B. hyrcana* and *C. speciosum*. *Pak. J. Sci.*, 23: 29-34. PMID: 20067863

- Galigher, A.E. and E.N. Kozloff, 1971. Essentials of practical Microtechnique. 2nd Edn., Lea and Febiger, Philadelphia, pp: 531.
- Ganie, S.A., E. Haq, A. Hamid, Y. Qurishi and Z. Mahmood *et al.*, 2011. Carbon tetrachloride induced kidney and lung tissue damages and antioxidant activities of the aqueous rhizome extract of podophyllum hexandrum. BMC Complementary Alternative Med., 11: 17-17. DOI: 10.1186/1472-6882-11-17
- Giacomelli, S., D. Gallo, P. Apollonio, C. Ferlini and M. Distefano *et al.*, 2002. Silybin and its bioavailable phospholipid complex (IdB 1016) potentiate in vitro and *in vivo* the activity of cisplatin. Life Sci., 70: 1447-1459. DOI: 10.1016/S0024-3205(01)01511-9
- Houghton, P.J., P.J. Hylands, A.Y. Mensah, A. Hensel and A.M. Deters, 2005. *In vitro* tests and ethnopharmacological investigations: Wound healing as an example. J. Ethnopharmacol., 100: 100-107. DOI: 10.1016/j.jep.2005.07.001
- Joly, A.B., 1985. Introduction to taxonomic vegetation.
- Kim, E.Y., E.K. Kim, H.S. Lee, Y. Sohn and Y. Soh *et al.*, 2007. Protective effects of cuscuteae semen against dimethylnitrosamine-induced acute liver injury in sprague-dawley rats. Biol. Pharmaceutical Bull., 30: 1427-1431. DOI: 10.1248/bpb.30.1427
- Lieber, C.S., M.A. Leo, Q. Cao, C. Ren and L.M. Decarli, 2003. Silymarin retards the progression of alcohol-induced hepatic fibrosis in baboons. J. Clin. Gastroenterol., 37: 336-339. DOI: 10.1097/00004836-200310000-00013
- Makinde, J.M., O.O.G. Amusan and E.K. Adesogan, 1988. The antimalarial activity of *Spathodea campanulata* stem bark extract on Plasmodium berghei berghei in mice. Planta Med., 54: 122-125. DOI: 10.1055/s-2006-962367
- Mbosso, E.J.T., S. Ngouela, J.C.S. Nguedia, V.P. Beng and M. Rohmer *et al.*, 2008. Spathoside, a cerebroside and other antibacterial constituents of the stem bark of *Spathodea campanulata*. Natural Product. Res., 22: 296-304. DOI: 10.1080/14786410701766281
- Mensah, A.Y., P.J. Houghton, R.A. Dickson, T.C. Fleischer and M. Heinrich *et al.*, 2006. *In vitro* evaluation of effects of two Ghanaian plants relevant to wound healing. Phytotherapy Res., 20: 941-944. DOI: 10.1002/ptr.1978
- Meyer, D. and J.W. Harvey, 2004. Hepatobiliary and Skeletal Muscle Enzymes and Liver Function Tests. In: Veterinary Laboratory Medicine: Interpretation and Diagnosis, Meyer, D.J. and J.W. Harvey (Eds.), WB.Saunders, St. Louis, ISBN-10: 0721689264, pp: 169-192.
- Naik, S.R. and V.S. Panda, 2007. Antioxidant and hepatoprotective effects of *Ginkgo biloba* phytosomes in carbon tetrachloride-induced liver injury in rodents. Liver Int., 27: 393-399. DOI: 10.1111/j.1478-3231.2007.01463.x
- Niyonzima, G., G. Laekeman, M. Witvrouw, B.V. Poel and L. Pieters *et al.*, 1999. Hypoglycemic, anticomplement and anti-HIV activities of *Spathodea campanulata* stem bark. Phytomedicine, 6: 45-49. DOI: 10.1016/S0944-7113(99)80034-8
- Ofori-Kwakye, K., A.A. Kwapong and F. Adu, 2009. Antimicrobial activity of extracts and topical products of the stem bark of *Spathodea campanulata* for wound healing. Afr. J. Traditional, Complementary Alternative Med., 6: 168-174. DOI: 10.4314/ajtcam.v6i2.57089
- Ohkawa, H., N. Oshishi and K. Yag, 1979. Assay for lipid peroxides in animal tissues by thiobarbituric acid reaction. Analytical Biochem., 95: 351-358. DOI: 10.1016/0003-2697(79)90738-3
- Orhan, D.D., N. Orhan, E. Ergun and F. Ergun, 2007. Hepatoprotective effect of *Vitis vinifera* L. leaves on carbon tetrachloride-induced acute liver damage in rats. J. Ethnopharmacol., 112: 145-151. DOI: 10.1016/j.jep.2007.02.013
- Oyaizu, M., 1986. Studies on products of browning reaction: Antioxidative activities of browning reaction prepared from glucosamine. Japanese J. Nutr. Dietet., 44: 307-315. DOI: 10.5264/eiyogakuzashi.44.307
- Ramaiah, S.K., 2007. A toxicologist guide to the diagnostic interpretation of hepatic biochemical parameters. Food Chem. Toxicol., 45: 1551-1557. DOI: 10.1016/j.fct.2007.06.007
- Recknagel, R.O., 1983. A new direction in the study of carbon tetrachloride hepatotoxicity. Life Sci., 33: 401-408. DOI: 10.1016/0024-3205(83)90787-7
- Rice-Evans, C.A., N.J. Miller, P.G. Bolwell, P.M. Bramley and J.B. Pridham, 1995. The relative antioxidant activities of plant-derived polyphenolic flavonoids. Free Radical Res., 22: 375-383. DOI: 10.3109/10715769509145649

- Rose, R., A. Banerjee and S.K. Ramaiah, 2007. Characterization of a lipopolysaccharide mediated neutrophilic hepatitis model in Sprague Dawley rats. *J. Applied Toxicol.*, 27: 602-611. DOI: 10.1002/jat.1243
- Rubinstein, D., 1962. Epinephrine release and liver glycogen levels after carbon tetrachloride administration. *Am. J. Physiol.*, 203: 1033-1037. PMID: 13983029
- Soto, C.P., B.L. Perez, L.P. Favari and J.L. Reyes, 1998. Prevention of alloxan-induced diabetes mellitus in the rat by silymarin. *Comparative Biochem. Physiol.*, 119: 125-129. DOI: 10.1016/S0742-8413(97)00198-9
- Timbrel, J., 2009. *Principles of Biochemical Toxicology*. 4th Edn., Informa, Boca Raton, ISBN-10: 0849373026, pp: 453.
- Tsai, J.H., J.Y. Liu, T.T. Wu, P.C. Ho and C.Y. Huang *et al.*, 2008. Effects of silymarin on the resolution of liver fibrosis induced by carbon tetrachloride in rats. *J. Viral Hepat.*, 15: 508-514. DOI: 10.1111/j.1365-2893.2008.00971.x